

# Graft

<http://gft.sagepub.com>

---

## **Update on Laryngeal Transplantation**

Marc Nelson, Michael Fritz, Robert Lorenz and Marshall Strome

*Graft* 2002; 5; 437

DOI: 10.1177/1522162802238648

The online version of this article can be found at:

<http://gft.sagepub.com>

---

Published by:

 SAGE Publications

<http://www.sagepublications.com>

**Additional services and information for *Graft* can be found at:**

**Email Alerts:** <http://gft.sagepub.com/cgi/alerts>

**Subscriptions:** <http://gft.sagepub.com/subscriptions>

**Reprints:** <http://www.sagepub.com/journalsReprints.nav>

**Permissions:** <http://www.sagepub.com/journalsPermissions.nav>

# Update on Laryngeal Transplantation

Marc Nelson, Michael Fritz, Robert Lorenz, and Marshall Strome

Total laryngectomy exerts a significant toll on the quality of life of patients undergoing this procedure. Current methods of rehabilitation do not adequately compensate for the associated functional and aesthetic losses. Total human laryngeal transplantation has been accomplished at the authors' institution and offers a potential reversal of the morbidity associated with total laryngectomy. The most important issue facing contemporary laryngeal transplantation remains the need for chronic immunosuppressive therapy. The index patient is now 4 years posttransplant and doing well, although he is being maintained on conventional immunosuppressive medications. Recent work in the pre-clinical rat model in the authors' laboratory has shown increased prevention of rejection, with newer immunomodulating protocols possessing low toxicity profiles. A novel 1-week protocol of combination immunotherapy has led to significantly prolonged graft survival without the need for maintenance therapy. Indeed, the field of laryngeal transplantation is poised for further advancements in the next few years that may significantly affect the initiation of laryngeal transplantation programs on a more widespread basis.

## Introduction

Early research in laryngeal transplantation by several authors used a preclinical dog model.<sup>1,2</sup> Vascular anastomoses were performed for replanted larynges, with no reinnervation attempts. Azathioprine was used as a single agent by Ogura et al.<sup>1</sup> and led to longer graft survival than in nonimmunosuppressed animals. Buoyed by the preliminary success with the animal models, Kluyskens and Ringoir<sup>3</sup> attempted the first human laryngeal transplantation (subtotal) in 1969 in a patient who underwent incomplete laryngectomy for cancer. Episodes of rejection were treated with azathioprine, prednisolone, actinomycine-C, and antilymphocyte serum. Rapidly fatal recurrence of cancer secondary to the immunosuppression overshadowed graft survival, and further transplantation attempts in humans were abandoned for decades. In retrospect, the long-term viability of Kluyskens and Ringoir's graft would have been unlikely, as no vascular or neural anastomoses were performed.

In 1970, Daly<sup>4</sup> argued that unless selective immunosuppression was available, pursuit of laryngeal transplantation was not ethically justified. Tucker<sup>5</sup> reinforced this opinion in his review of the

current status of laryngeal transplantation in 1974. He stated that the 4 criteria necessary for laryngeal transplantation to become feasible were (1) adequate revascularization, (2) adequate reinnervation, (3) safe immunosuppression without compromising tumor surveillance by the host system, and (4) justification for transplanting a nonessential organ. He felt that further attempts were not justified in humans until the third criterion was satisfied.

Studies from this era did not have the advantage of the advancements in microvascular technique and immunosuppression that have been realized over the past 15 years. Additionally, progress has been made in reinnervation techniques of the transplanted organ. In 1987, Strome and Strome<sup>6</sup> embarked on developing a rat model to explore the potential of total laryngeal transplantation (Fig. 1). Over the past 15 years, the model has been refined, reflecting improvements in technique, preservative solutions, and immunosuppressive regimens. With these advancements in laryngeal transplantation came the realization that this procedure was technically feasible in humans, despite remaining challenges with immunosuppression and reinnervation. Taking into account these limitations, Potter and

Marc Nelson  
Cleveland Clinic Foundation  
9500 Euclid Avenue, Desk A-71  
Cleveland, OH 44195, USA  
e-mail: nellie7367@aol.com  
DOI: 10.1177/1522162802238648

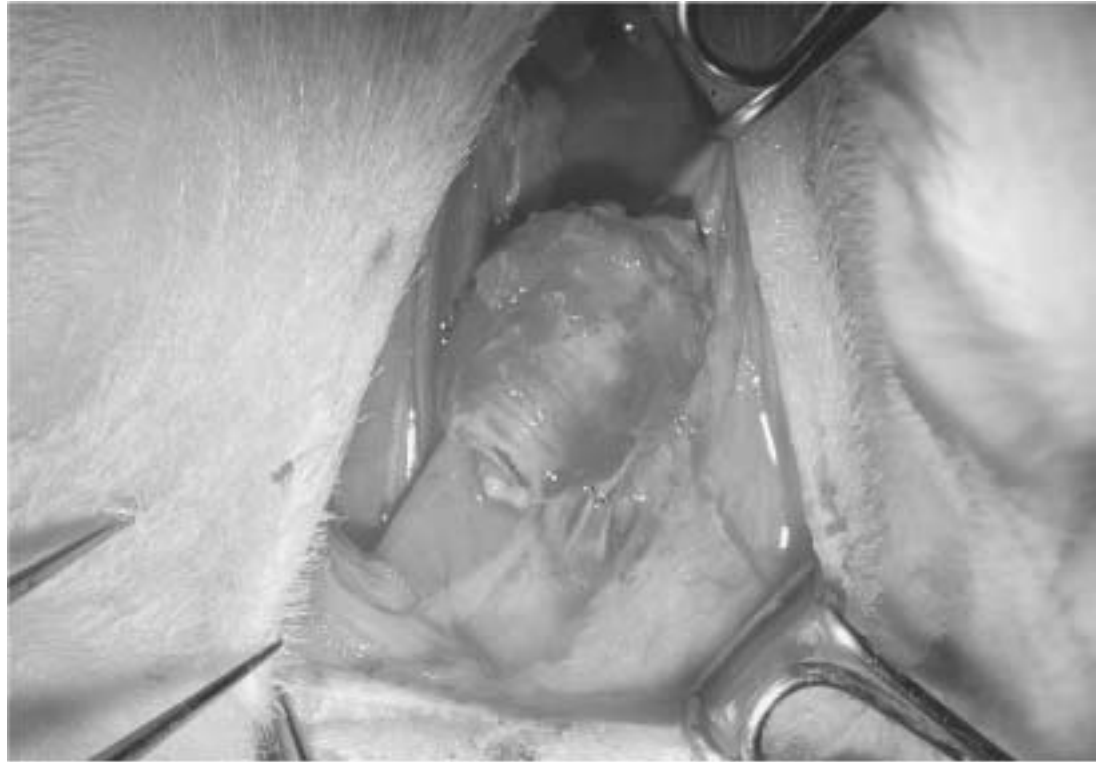

Figure 1. Laryngeal graft after revascularization. In the rat model, the graft is pedicled on the superior thyroid arteries. The common carotid of the donor graft is anastomosed end-to-side to the common carotid of the recipient, whereas venous drainage is accomplished via an end-to-side arteriovenous anastomosis with the recipient external jugular vein.

Birchall<sup>7</sup> hypothesized in 1998 that laryngectomy patients would find laryngeal transplantation an unacceptable option when compared to the current methods of voice rehabilitation. In a study of 372 laryngectomy patients who filled out questionnaires, however, the authors found a surprisingly high level of support for transplantation. Seventy-five percent of this population said they would accept a transplant under ideal conditions, whereas 50% indicated they would accept a transplant even if it did not result in normal phonation.

On January 4, 1998, a team led by Strome et al.<sup>8</sup> performed a total laryngeal transplantation in a man who had sustained severe laryngeal trauma in a motor vehicle accident.

#### Human Laryngeal Transplant

The transplant recipient, a 40-year-old man who sustained a laryngeal crush injury 20 years earlier, remained aphonic and tracheostomal dependent

despite multiple attempts at reconstruction at outside institutions. After extensive pretransplant evaluation and counseling, which included psychiatric evaluation, speech pathology testing, and multiple interviews with the transplant team, the patient was deemed an appropriate candidate for the procedure. A 6-month search for a suitable donor began after Cleveland Clinic Foundation institutional review board approval was obtained. The donor was a 40-year-old man who had died from a ruptured cerebral aneurysm and met all of the predetermined human leukocyte antigen (HLA) matching and serum virology criteria.

The harvested donor specimen included the entire pharyngolaryngeal complex, the first 6 tracheal rings, and the thyroid and parathyroid glands. Prior to transport, the organ complex was flushed with and stored in University of Wisconsin solution. Ten hours later, after surgical exposure of the recipient's laryngeal remnant and suitable vessels, the graft was

revascularized. Perfusion of the donor organ was established through microvascular anastomosis of the recipient's right superior thyroid artery to that of the patient. Venous drainage was accomplished by connecting the proximal end of the donor right internal jugular vein (in continuity with the middle thyroid vein) to the patient's right common facial vein. Within 30 minutes of clamp release, blood flow through the entire allograft complex was observed.

The recipient's scarred laryngeal remnant was then removed via narrow field laryngectomy. Stenosis of the pharynx and upper esophagus mandated grafting of 75% of the donor pharynx along with the laryngotracheal complex. The donor larynx was suspended from the recipient's hyoid bone and 5 donor tracheal rings were employed to reach the superior aspect of the patient's tracheostoma. After the allograft was inset, the remaining microvascular anastomoses were established on the left side between the donor superior thyroid artery and the patient's superior thyroid artery and the donor middle thyroid vein and the recipient's internal jugular vein. Both donor superior laryngeal nerves were anastomosed to the patient's superior laryngeal nerves. The recipient's right recurrent laryngeal nerve was connected to the donor's, but the recipient's left recurrent laryngeal nerve could not be located.

Prior to surgery, the transplant recipient had received cyclosporine (CSA), azathioprine, and methylprednisolone. In the immediate postoperative period, he was maintained on muromonab-CD3, CSA, methylprednisolone, and mycophenolate mofetil (MMF). One month after transplant, the transplanted trachea was normal on both endoscopy and biopsy. The patient's only episode of rejection, heralded by a decrease in voice quality 15 months after transplantation, resolved after 3 doses of 1 g of methylprednisolone/day. He is now 55 months posttransplant and is maintained on MMF 1 g/day, tacrolimus 4 mg/day, and prednisone 7.5 mg/day, with stable blood pressure and renal function.

Sensation had returned to the supraglottis and vocal folds 3 months after the surgery. Subsequent barium swallows revealed no aspiration, and the patient currently maintains a regular diet. His senses of smell and taste have returned with the reestablishment of nasal airflow. A 4-hour iodine-123 up-

take study was performed to evaluate thyroid function. Eighty-three percent of thyroid activity was located in the transplanted thyroid lobes, with the remaining 17% contributed by the native organ. Thyroid function tests and serum calcium have remained normal.

The patient first spoke with his transplanted larynx on postoperative day 3. Six months after surgery, the right vocal fold (reinnervated at surgery) was midline and the left fold was in paramedian position. At 36 months posttransplant, subjective and objective voice measures including intensity, pitch, jitter, and maximal phonation time are within the range of normal. Recent electromyography (EMG) studies have demonstrated reinnervation of both vocal folds (without voluntary motion). The left side (no recurrent laryngeal nerve located in surgery) is thought to be supplied by surrounding motor nerves. EMG has also demonstrated volitional cricothyroid function, which is responsible for the patient's current pitch control.

The patient, extremely satisfied with the results of his surgery, reports that his quality of life has improved "immeasurably." He has become a motivational speaker. At this point, he retains a tracheostoma, whereas sling tracheoplasty and laser cordotomy remain options for further management.

### Immunosuppressive Research

Of the 4 requirements for feasible laryngeal transplantation put forth by Tucker,<sup>5</sup> the greatest limiting factor is the need for chronic immunosuppressive therapy with its associated nonimmunologic toxicities and deleterious effect on cancer surveillance. Improved immunomodulating protocols have been the focus of study in our laboratory for several years. The rat model provides an excellent system for evaluation with low cost, a near 100% survivability of the animals, and a greater than 90% graft evaluability.<sup>9</sup> Lorenz et al.<sup>10</sup> developed a histopathologic grading system of acute rejection that is both reliable and reproducible and allows comparison between various immunosuppressive regimens.

Early work with CSA using this model demonstrated a protective effect against acute rejection at 30 days when dosages of 5.0 mg/kg or greater were used.<sup>11</sup> To minimize CSA dose and associated toxicities, studies evaluated CSA as a component of

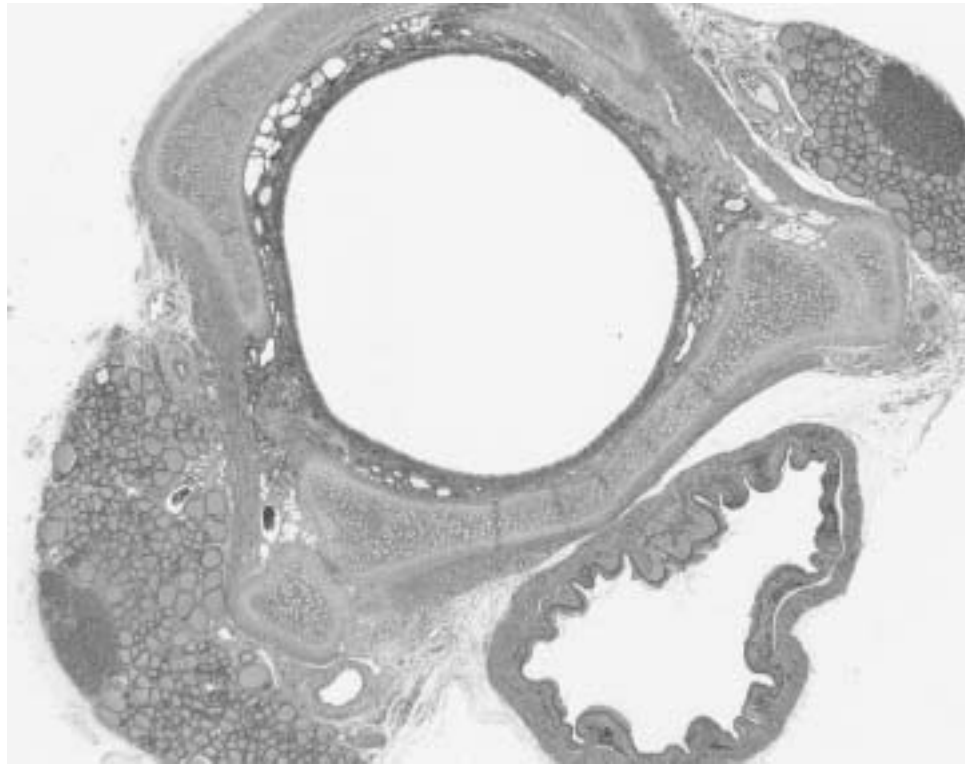


Figure 2. Photomicrograph of harvested graft after 30 days in an animal treated with 0.1 mg/kg of tacrolimus and 40 mg/kg of mycophenolate mofetil. Note the preservation of the mucosa, minor salivary glands, thyroid, and parathyroid tissue.

combination therapy, with the goal of reducing the required dosage without compromising graft viability. Barthel et al.<sup>12</sup> found that delivering 7.34 Gray in vitro radiation to the donor graft immediately prior to transplantation allowed the effective dosage of CSA to be lowered from 5.0 mg/kg to 2.5 mg/kg while preventing acute rejection at 30 days. Similarly, the use of prednisone allowed the dosage of CSA to be decreased further. With the addition of 1.0 mg/kg p.o. per day of prednisone, CSA could be reduced to 2.0 mg/kg without compromising graft preservation at 30 days.<sup>13</sup>

The majority of animal studies in laryngeal transplantation from the literature are cyclosporine based. More recently, we have been evaluating tacrolimus. Studies in multiple transplant settings have demonstrated improved results with tacrolimus compared to CSA.<sup>14,15</sup> We found tacrolimus to be effective alone at dosages of 0.6 mg/kg in preventing rejection. Normal histology with no signs of re-

jection was seen in 7 of 9 rats receiving this dosage at 30 days posttransplant. The addition of MMF allowed the tacrolimus dosage to be lowered without compromising protection against rejection. Our multiarm studies suggest that 0.1 mg/kg of tacrolimus and 40 mg/kg of MMF, or, alternatively, 0.2 mg/kg of tacrolimus and 30 mg/kg of MMF, provided equivalent protection against acute rejection in comparison to 0.6 mg/kg of tacrolimus (Fig. 2). The significance of this study is that MMF, which does not affect renal function, allows low dosages of tacrolimus to be used, thereby limiting the toxicities of this medication. Recently completed studies suggest that the addition of prednisone to this regimen does not allow further dose reduction of this combination.

The ideal goal of immunomodulating therapies for allotransplantation is donor-specific tolerance, where permanent engraftment can be established without chronic immunosuppression. In our rat

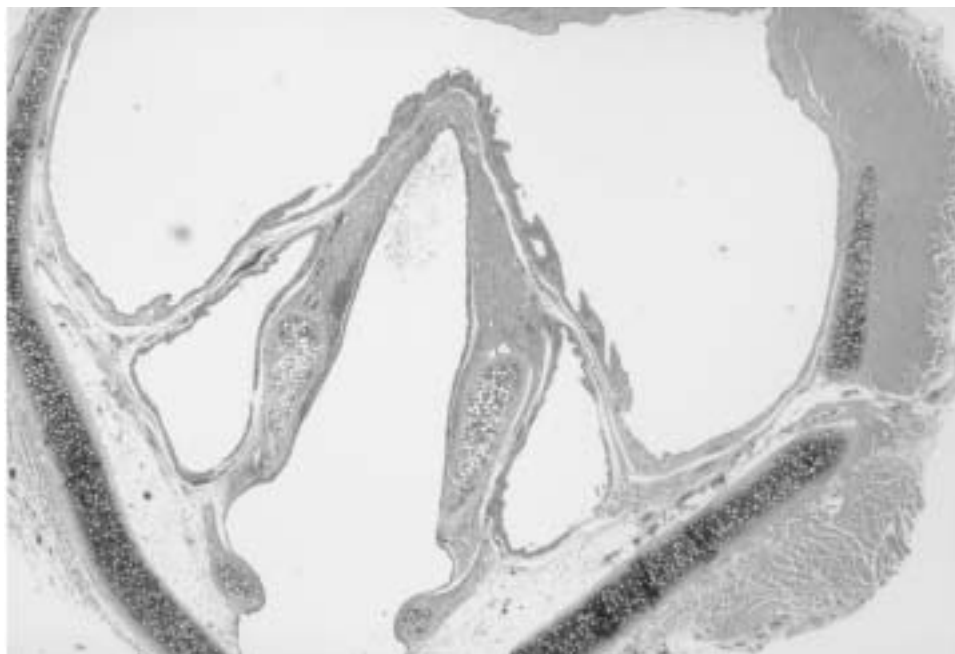


Figure 3. Photomicrograph of harvested rat graft at the level of the larynx after 100 days in an animal treated with a novel 1-week course of immunosuppression posttransplant. Mucosa, submucosa, muscle, and fat all demonstrate normal histology.

model, we investigated a new regimen in which recipients are treated with a 1-week course of high-dose tacrolimus and a new monoclonal antibody. No further treatment is given after this 7-day period. Preliminary results demonstrate normal histology (no rejection) at 100 days posttransplant, with additional allografts currently viable after longer follow-up periods (Figs. 3, 4). A new functional biologic marker of laryngeal allograft viability developed in our lab allows long-term monitoring of the graft viability through serum testing. If long-term tolerance is not attainable with the above 1-week immunotherapeutic regimen, pulse therapy, guided by the biological marker, may allow indefinite allograft preservation.

Research in tracheal transplantation is being actively pursued in other laboratories. Two recent studies have investigated methodologies that do not employ chronic immunosuppression. Kunachak et al.<sup>16</sup> used a combination of cryopreservation followed by irradiation of the cadaveric donor tracheal allograft in 4 patients. At 18 months, 3 of the patients remained decannulated without any immunosuppression. Hashimoto et al.<sup>17</sup> used a short

course of high-dose FK506 (1.5 mg/kg for 3 days) to significantly reduce acute rejection at 28 days in rats when compared to lower dosages. Findings in our lab suggest that the trachea is much more resistant to rejection phenomena than the larynx or endocrine tissues.

We are currently beginning studies with rapamycin, which has been reported in other transplant settings to provide equivalent immunosuppression with far less toxicity compared to the calcineurin inhibitors.<sup>18</sup> Additionally, rapamycin is known to possess antitumor properties. Although this effect has not yet been described for squamous cell carcinoma, rapamycin may help to inhibit occult microscopic disease that might remain after definitive treatment of laryngeal cancer.

With advanced-stage laryngeal cancer being the most common indication for total laryngectomy and eventual laryngeal transplantation, it will be necessary to develop immunosuppressive regimens that will not potentiate malignancy. Regimens that are short term, induce donor-specific tolerance, or possess antiproliferative properties offer potential solutions.

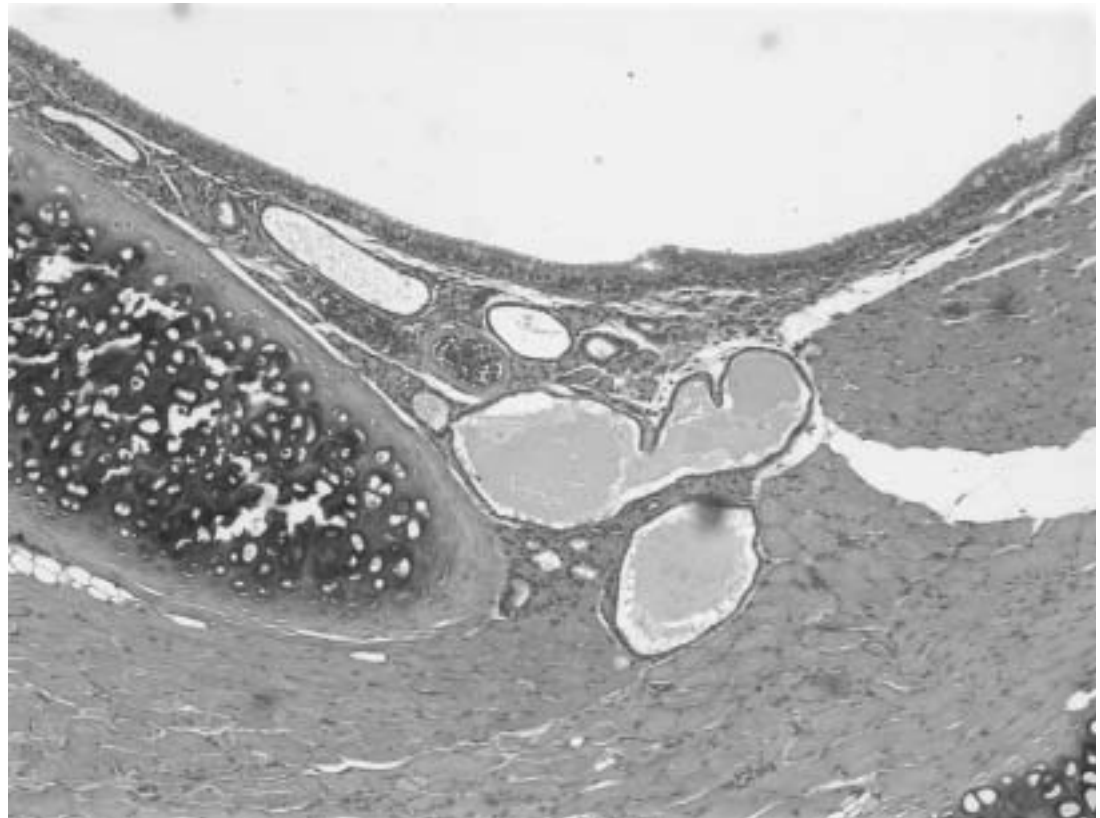


Figure 4. A graft harvested at 100 days following a short-term course of immunotherapy. Note the normal mucosal structures (cilia, goblet cells) and functioning minor salivary glands.

### Reinnervation Research

Laryngeal transplantation poses a challenge that is unique among organs in that restoration of a completely functional graft hinges on successful reinnervation. Early attempts at reinnervation using recurrent laryngeal nerve (RLN) primary anastomoses between donor and recipient nerves led to poor results, including laryngeal synkinesis and total loss of nerve function.<sup>19</sup> To allow eventual closure of the tracheostoma and provide reasonable protection against aspiration while preserving a functional voice, refinements in reinnervation technique were required. Over the past several decades, multiple techniques of selective reinnervation have been attempted, with mixed results. Many types of nerve-nerve anastomoses have been studied in canine models, including ansa cervicalis-RLN stump, RLN-RLN anastomoses with sectioning of the ad-

ductor branch on the graft side, and phrenic nerve-posterior branch (abductor) of RLN with or without the ansa hypoglossi-anterior (adductor) branch of RLN. Unfortunately, it is difficult to critically compare these various techniques, as most studies to date have involved a small number of evaluable animals, parallel studies have not been widely conducted, and objective reporting of laryngeal findings is not standardized.

Tucker<sup>5</sup> introduced the concept of nerve-muscle pedicle (NMP) transfers in the early 1970s. Originally, a neuromuscular island pedicle encompassing all terminal branches of the RLN was excised, then laid back down in the defect. He reported successful voluntary vocal function within 2 weeks. A later modification was to use an NMP consisting of the ansa hypoglossi nerve and a surrounding portion of sternohyoid muscle implanted into the pos-

terior cricoarytenoid (PCA) muscle of the graft, which is the main abductor of the larynx. Tucker noted that 50% of animals undergoing this procedure during reimplantation of the larynx had excellent abduction. However, repeated attempts by researchers at other institutions have failed to reproduce the success rates reported by Tucker. More recent work by Berke et al.<sup>20</sup> used an NMP (based on the posterior branch of RLN) implanted into the PCA muscle of the graft, in combination with a primary neural anastomoses of the anterior branches of the RLN. In a small number of reportable experiments, these authors found good control of vocal fold adduction, whereas reflex abduction was present (demonstrated with EMG) when the tracheostoma was occluded. Further follow-up is pending.

In addition to restoration of motor input to the larynx, sensory reinnervation is key for physiologic airway protection. Blumin et al.<sup>21</sup> studied dogs who underwent reanastomosis of the superior laryngeal nerve (SLN) after sectioning. The animals did not regain normal airway reflexes but exhibited protective EMG activity and coughing, whereas the control group (no anastomosis) displayed no response. In our transplant patient, the supraglottis and vocal folds were sensitive to contact at 3 months, causing a severe cough, thus allowing the patient to protect his airway after reanastomoses of the SLNs.

Primary nerve reanastomosis has not yet been optimized. Additionally, safe oncologic procedures may require excision of a significant portion of the donor nerves; thus, nerve interposition grafts may be necessary. A novel technique for peripheral nerve repair in which a single fascicle is employed to interpose a defect has been investigated in a rat sciatic nerve model at our institution.<sup>22</sup> Improved functional recovery and histomorphometric outcome in animals repaired with a single fascicle compared to animals repaired with a conventional nerve autograft have been observed. It is theorized that the single fascicle, which acts as a scaffold to allow axon regeneration to proceed in the proper vector, more readily circumvents the inadequate tissue perfusion often seen in free grafts. Improved Schwann cell survival is imperative to create an environment ideal for nerve regeneration through the elaboration of neurotrophic factors and removal of cellular and

axonal debris. Further work in this area could have significant implications for selective reinnervation of the transplanted larynx.

## Conclusions

Now 55 months after its attempt, successful total laryngeal transplantation has become a reality. The patient reports a vastly improved quality of life, including smell, taste, daily communication, and emotional expression through a voice that is uniquely his own. Of course, investigations in the areas of immunosuppression and reinnervation must continue. Given the vast resources currently committed to the field of transplantation as a whole, the day is not far off when immunosuppression will be applied without comorbidities; undoubtedly, the lessons we learn today will benefit the many potential candidates for laryngeal transplantation in the future.

## REFERENCES

- Ogura JH, Kawasaki M, Takenouchi S, et al. Replantation and transplantation of the canine larynx. *Ann Otol Rhinol Laryngol* 1966;75:295-312.
- Silver GE, Lieber PS, Som ML. Autologous transplantation of the canine larynx. *Arch Otolaryngol* 1967;86:95-102.
- Kluyskens P, Ringoir S. Follow-up of a human larynx transplantation. *Laryngoscope* 1970;80:1244-50.
- Daly JF. Is laryngeal transplantation justifiable? *Laryngoscope* 1970;80:1251-5.
- Tucker HM. Laryngeal transplantation: current status 1974. *Laryngoscope* 1974;85:787-96.
- Strome M, Strome S. Laryngeal transplantation: a program for investigating new parameters. *J Voice* 1994;8(1):92-4.
- Potter CP, Birchall MA. Laryngectomee's views on laryngeal transplantation. *Transplant Int* 1998;11:433-8.
- Strome M, Stein J, Esclamado R, et al. Laryngeal transplantation: a case report with three-year follow-up. *N Engl J Med* 2001;344:1676-9.
- Strome S, Sloman-Moll E, Samonte BR, et al. Rat model for a vascularized laryngeal allograft. *Ann Otol Rhinol Laryngol* 1992;101:950-3.
- Lorenz R, Dan O, Fritz M, Strome M. The murine laryngeal transplant model: a refined histologic rejection grading system.
- Strome M, Strome S, Darrell J, et al. The effects of cyclosporin A on transplanted rat allografts. *Laryngoscope* 1993;103:394-8.
- Barthel SW, Dan O, Myles J, et al. Effect of in vitro irradiation of donor larynges on cyclosporine requirements and rejection rates in rat laryngeal transplantation. *Ann Otol Rhinol Laryngol* 2001;110:20-4.
- Lorenz RR, Dan O, Haug M, et al. Effects of adding steroid, in vitro irradiation, or both to cyclosporine immunosuppression in the murine laryngeal transplantation model: a controlled trial. *Ann Otol Rhinol Laryngol* 2002;111(5 Pt 1): 455-9.
- Mayer A, Dmitrewski J, Squifflet J, et al. Multicenter randomized trial comparing tacrolimus (FK506) and cyclosporine in the prevention of renal allograft rejection: a report of the European Tacrolimus Multicenter Renal Study Group. *Transplantation* 1997;64:436-43.
- US Multicenter Liver Study Group. A comparison of tacrolimus (FK506) and cyclosporine for immunosuppression in liver transplantation. *N Engl J Med* 1994;331:1110-5.

16. Kunachak S, Kulapaditharom B, Vajaradul Y, et al. Cryopreserved, irradiated tracheal homograft transplantation for laryngotracheal reconstruction in human beings. *Otolaryngol Head Neck Surg* 2000;122:911-6.
17. Hashimoto M, Nakanishi R, Muranka H, et al. Short-course immunosuppression using FK506 for rat tracheal allografts. *J Cardiovasc Surg* 2000;41:487-92.
18. Johnson RW, Kreis H, Oberbauer R, et al. Sirolimus allows early cyclosporine withdrawal in renal transplantation resulting in improved renal function and lower blood pressure. *Transplantation* 2001;72:777-86.
19. Rice DH. Laryngeal reinnervation. *Laryngoscope* 1982;92:1049-59.
20. Berke GS, Ye M, Block RM, et al. Orthotopic laryngeal transplantation: is it time? *Laryngoscope* 1993;103:857-64.
21. Blumin JH, Ye M, Berke GS, et al. Recovery of laryngeal sensation after superior laryngeal nerve anastomosis. *Laryngoscope* 1999;109:1637-41.
22. Scharpf J, Meirer R, Unsal, M, et al. A novel technique for peripheral nerve repair. *Laryngoscope* (in press).